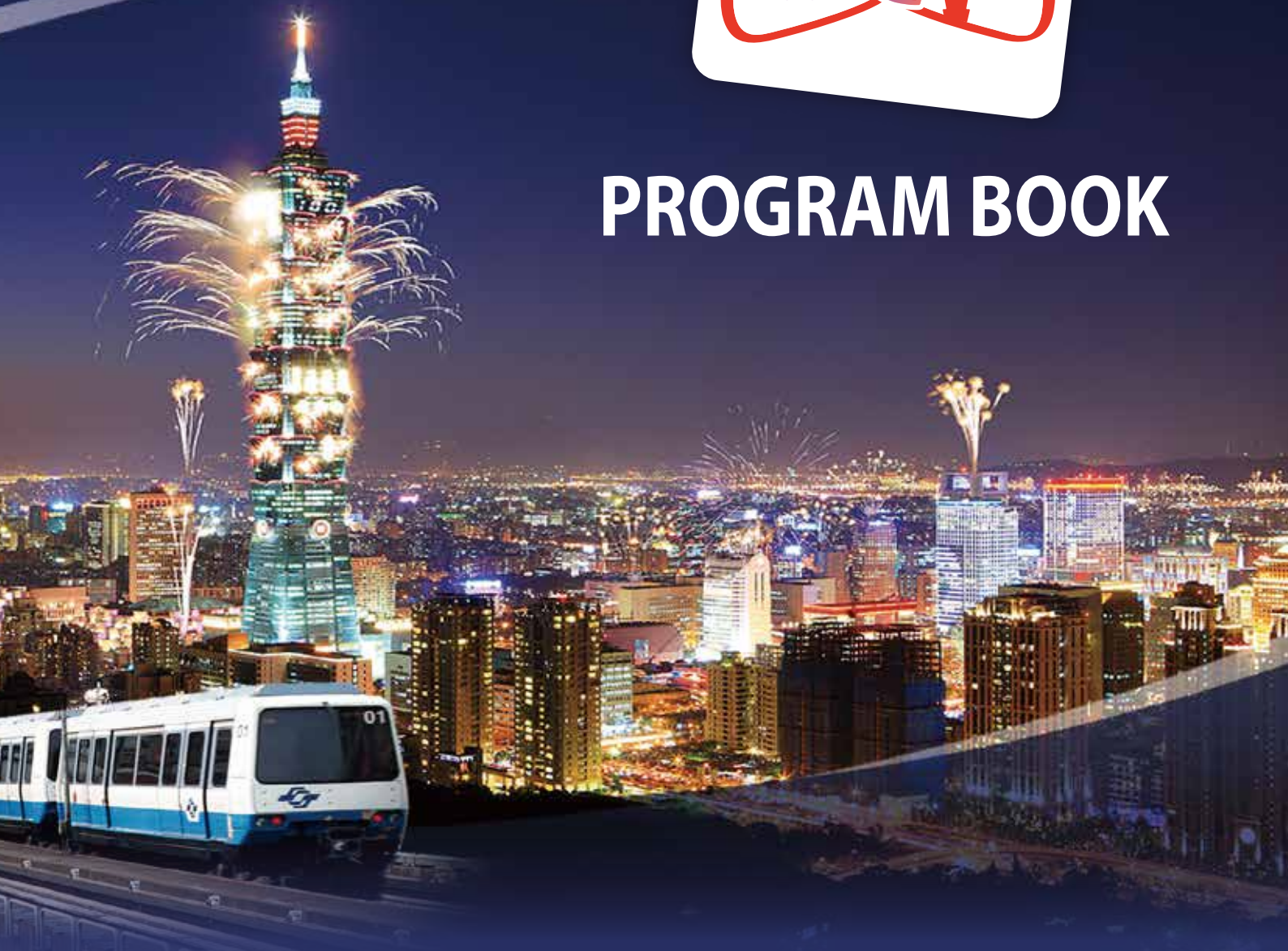


www.ascvts2016.org



PROGRAM BOOK



The 24th Annual Meeting of Asian Society for Cardiovascular and Thoracic Surgery (ASCVTS)
in conjunction with **9th AATS / ASCVTS Postgraduate Course** and **4th Asian Single Port VATS Symposium**



April 06-10, 2016, Taipei, Taiwan

- PS 2-11** CASE REPORT: DUCTUS ARTERIOSUS ANEURYSM SHOWED HISTOLOGIC FEATURE OF AORTA
Byoung-Ju Min, Jinwook Hwang, Won-Min Jo, Jaeseung Shin, *Korea University Medical Center (South Korea)*
- PS 2-12** THE MORPHOLOGY OF TRICUSPID VALVE AT TVR IN PHYSIOLOGIC SURGERY FOR CCTGA PATIENTS (PLASTY OR REPLACEMENT?)
Keiichi Hirose, Takeshi Nishina, Hisashi Sakaguchi, Akihiro Mizuno, Sachiyo Yoshida, Masashi Yada, Yohei Onga, Kazuo Yamanaka, *Tenri Hospital (Japan)*
- PS 2-13** ON PUMP HYPOTHERMIC FIBRILLATORY ARREST: CASE SERIES
Imam Suseno Bayuadi, Arif RH, Subroto H, *Airlangga University Surabaya (Indonesia)*
- PS 2-14** EMERGENCY SURGICAL REMOVAL OF AN EMBOLIZED PATENT DUCTUS ARTERIOSUS DUCT OCCLUDER DEVICE FROM LEFT PULMONARY ARTERY WITHOUT CARDIOPULMONARY BYPASS
Vijayant Devenraj, Sushil Kumar Singh, Vivek Tewarson, Sarvesh Kumar, Bhupendra Kumar, Prabhdeep Singh, Ved Prakash, Navneet Kaur, *King George's Medical University (India)*
- PS 2-15** THE CASE OF IATROGENIC STENOSIS OF THE LEFT MAIN BRONCHUS AFTER EMBOLIZATION MAPCA IN A CHILD WITH COMPLEX CHD
Dar'ya Ivaschenko, David Berishvili, Bagrat Alekryan, Kuba Mumladze, *Bakoulev SCCVS (Russia)*
- PS 2-16** THE ROLE OF ECHOCARDIOGRAPHY IN THE DIAGNOSIS OF CONGENITAL ANOMALIES OF THE CORONARY ARTERIES WITH CONGENITAL HEART DEFECTS
Lyazin D.V, Baryshnikova I.Y, Plakhova V.V, Nefedova I.E, Berishvili D.O., *Bakoulev SCCVS (Russia)*
- PS 2-17** THE CASE OF A SUCCESSFUL CORONARY ARTERY BYPASS GRAFTING AT THE THREE YEAR OLD CHILD WITH KAWASAKI SYNDROME
Olga Bockeria, Leo Bockeria, Vadim Merzlyakov, Anna Satyukova, Tea Kopaliani, Albert Akhobekov, *Bakoulev SCCVS (Russia)*, Galina Lyskina, Olga Shirinskaya, *I.M. Sechenov First Moscow State Medical University (Russia)*
- PS 2-18** EARLY OUTCOME FOLLOWING REPAIR OF COARCTATION AND ARCH RECONSTRUCTION IN INFANTS
Vijayakumar Raju, Kalyanasundaram Muthusamy, *GKNM Hospital (India)*
- PS 2-19** A RARE CASE OF AORTO PULMONARY WINDOW OPERATED AT 9 YEARS OF AGE
Gopi Nallaiyan, *Velammal Medical College Speciality Hospital (India)*
- PS 2-20** RUPTURED AND CLACIFIED SINUS OF VALSALVA WITH A LARGE VSD AND ITS SURGICAL REPAIR : DOUBLE PATCH TECHNIQUE
Ahson Memon, Junaid `Ansari, Ghufuranullah Khan, Khalid Rasheed, Rafat Shakil, Azeem Khan, Saad Shaikh, *Tabba Heart Institute (Pakistan)*
- PS 2-21** MAZE IIIB PROCEDURE: OUR APPROACH AND RESULTS IN 420 PATIENTS
Olga Bockeria, Leo Bockeria, Mikhail Biniashvili, Merab Sanakoev, Vladimir Shvartz, Artak Ispiryan, Igor' Klymchuk, *Bakoulev SCCVS (Russia)*
- PS 2-22** LOCATION OF RUPTURED BULLAE IN SECONDARY SPONTANEOUS PNEUMOTHORAX; IS IT ASSOCIATED WITH CARDIOGENIC MOTION?
Jeong Su Cho, Hyo Yeong Ahn, Yeong Dae Kim, Hoseok I, Jonggeun Lee, *Pusan National University Hospital (South Korea)*